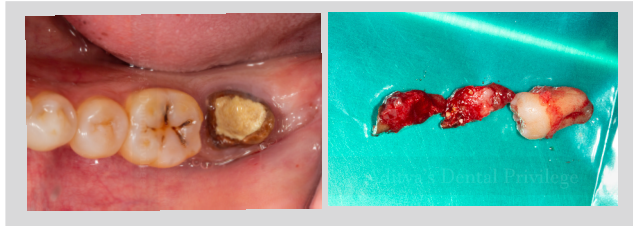
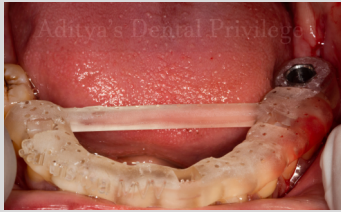 D TECH DENTAL TECHNOLOGIES	Case Record		Case Date	02 Jan 2022
	Clinic:Aditya's Dental Privilege, Pune		Case Ref	Jan 22/C&B P
	Case No	CR-3DR- C&B - 04	Rev No &Date	02/10. 2023

3D Printed - Healing Abutment using C&B (Pro)& Surgical Guide using SG Resin



Tooth Extraction

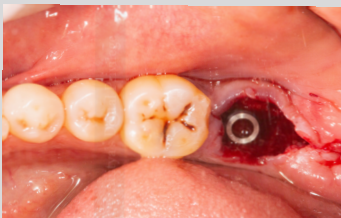3D Printed Surgical Guide



3D Printed Abutment



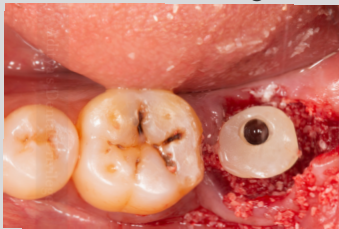C&B (Pro)



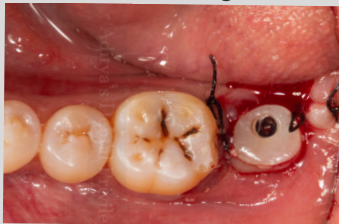Placement

Implant Procedure

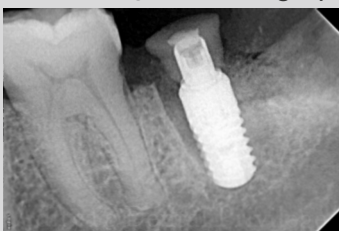
Bone Grafting



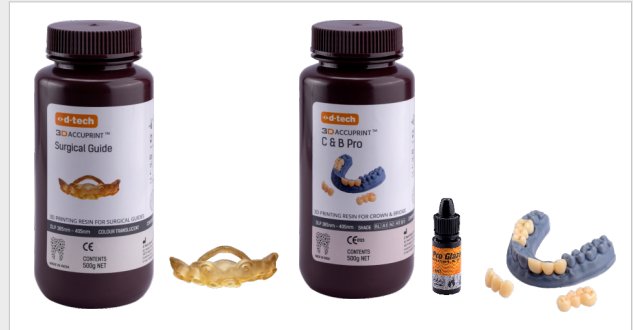Suturing



Post Surgical Radiograph



Product used : Surgical Guide and C&B (Pro)



About The Case

The patient reported to the clinic with a debonded crown and fractured tooth/abutment number 37. On CBCT a fracture in tooth furcation was confirmed and an immediate implant was planned. Digital planning was done and a guide using surgical guide resin was printed in the clinic. Custom healing abutment was also planned and printed before the surgery. Fully guided implant placement was done post-extraction, the socket was grafted and custom healing abutment was placed.

Outcome & Doctor's Comment

Two resins from D-tech was used, firstly Surgical Guide for printing of Implant guide and C&B (Pro) for printing of custom healing abutment. The guide fitted perfectly without any adjustments and was quite translucent post autoclaving, The custom abutment was printed with the C&B (Pro) resin which again fitted on the Ti-base like a glove.

About the Doctor

Dr Priyam Aditya, MDS (Prosthodontics) has ample international experience in implantology with training at Eastman Dental and later at Beograd, Serbia. He is a certified Exoplan trainer. His full-time private practice in Pune, India is fully devoted to digital dentistry with intra-oral scanners and in house 3D printing setup.

