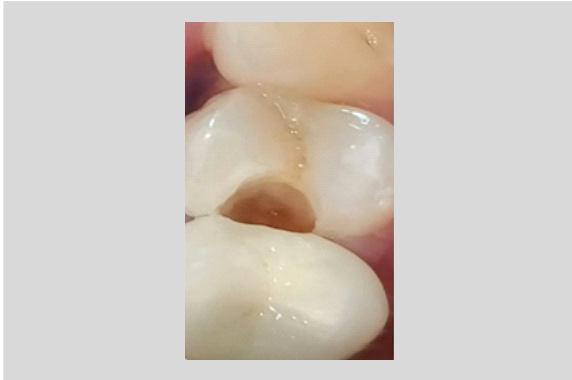
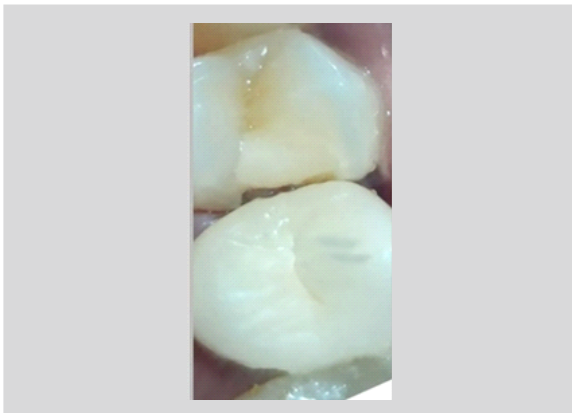
 <b>D TECH DENTAL TECHNOLOGIES</b>	<b>Case Record</b>		<b>Case Date</b>	<b>05 Mar 2025</b>
	Doctor Name Dr Prashant Sharma, Delhi		<b>Case No</b>	<b>CR-D-87</b>
	Rev No & Date	<b>00 Mar 2025</b>	<b>Case Ref</b>	<b>Mar 15 /R+</b>

## Posterior Restoration

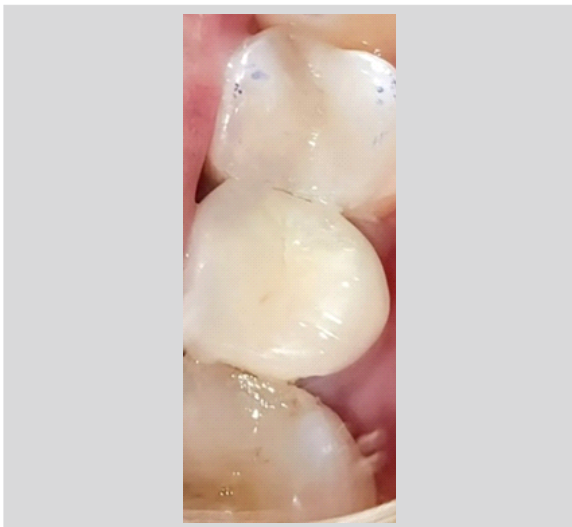
Pre-Treatment Photo



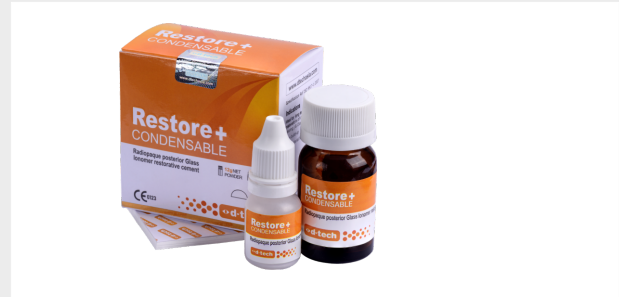Tooth Prep Photo



Post -Treatment Photo



## Product used : Restore+



### About The case

Patient Name : Anita Jadhav

Age/Gender : 29/F

Diagnosis : Food Lodgements in Posterior

Treatment Plan : Patient came with complaints of food lodgements in posterior. The dentist has done an X Ray via RVG and found no infection in the canal so suggested a tooth filling. product used was by D Tech Restore +.

### Outcome & Doctor's Comment

"Restore + is a high strength posterior GIC and can be used for any type of restorations."

Highly recommended for posterior fillings . The strength can easily be compared with GC ,Shofu ,Voco and other leading brands.

### About the Doctor

Dr Prashant Sharma is a BDS (MIDA), MBA health services . Passed out from Santosh Dental College. He is a good practitioner in Shalimar Garden, GZB.

