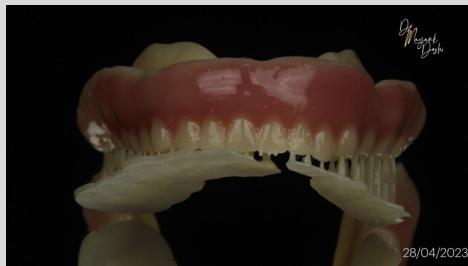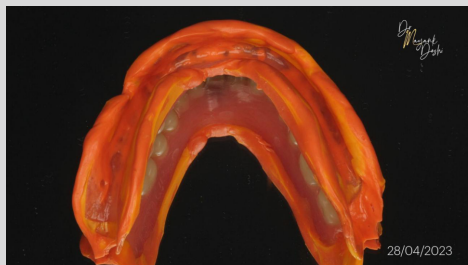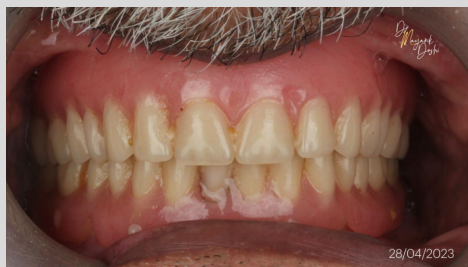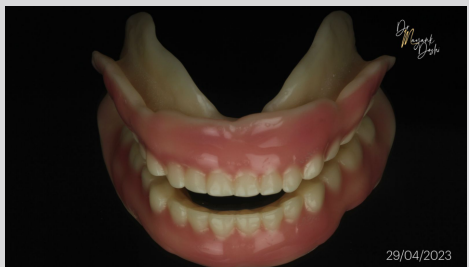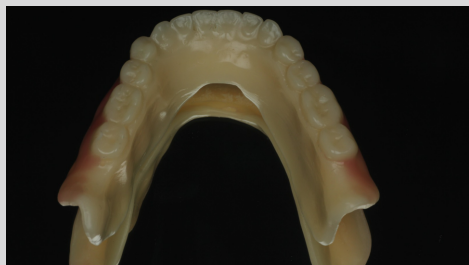 D TECH DENTAL TECHNOLOGIES	Case Record		Case Date	28 Apr 2023
	Doctor Name : Dr.Mayank Doshi, Mumbai		Case Ref	July 24/DB
	Case No	CR-3DR-DB -04	Rev No &Date	NA

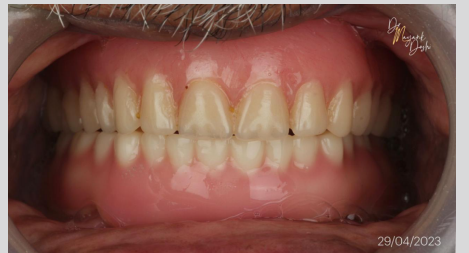3D Printing - Full Denture case in 24 hours



Pre Treatment photos

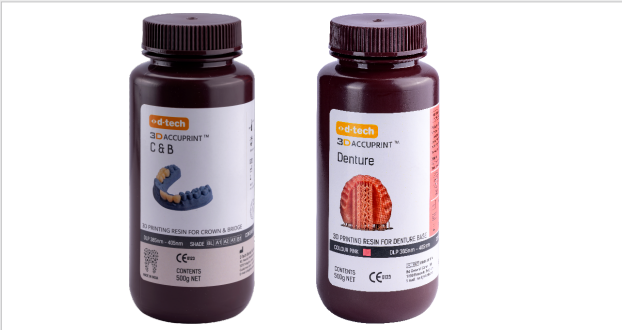

Tooth preparation photos



Post Treatment photos

Product used : Denture &C&B resin



About The case


Patient came to the clinic with a complaint of loose lower denture which was made a few months ago elsewhere and it was affecting his chewing a lot. So he wanted to make a new lower denture.

Outcome & Doctor's Comment

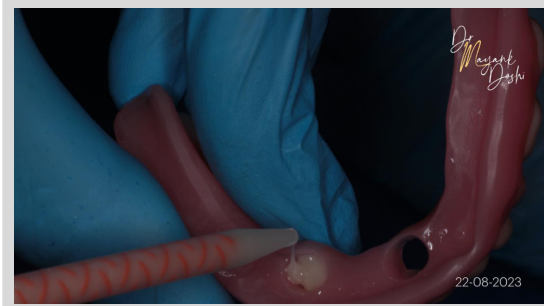
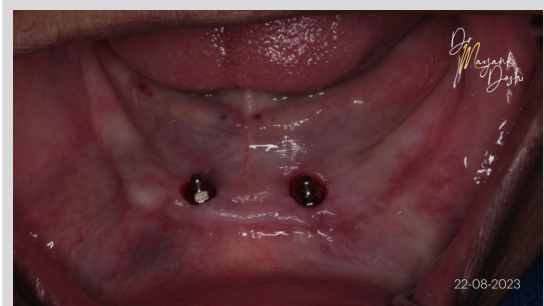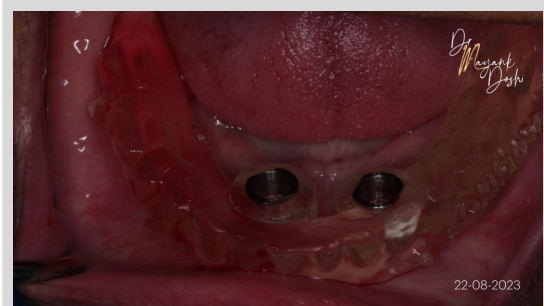
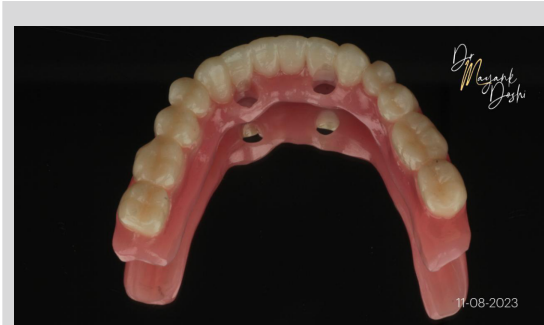With the help of his old denture a wash impression was made and we kept the jaw relation constant as he was okay with that. The new wash impression over the old lower denture and the old upper denture was scanned and the data imported into Exocad for denture designing. later, the monoblock denture was 3D printed using D tech 3D accuprint C&B resin in phrozen sonic Mini 8K. Post that ,the denture was layered buccally with 3D accuprint Denture base resin followed by finishing & polishing. Post the denture delivery the patient was extremely satisfied with the fit and comfort. It was also observed how his chewing efficiency improved later.

About the Doctor

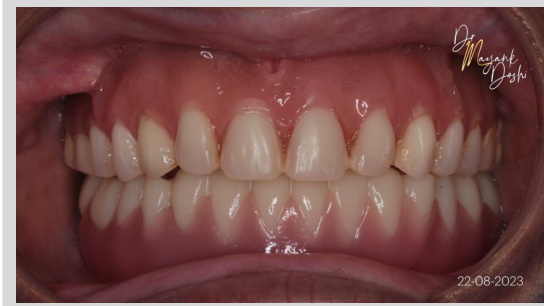Dr. Mayank Doshi is a dentist , Cosmetic and aesthetic dentist and Dental Surgeon in Kandivili west , Mumbai and has an experience of 14 years in these fields.

<div></div> <div>D TECH DENTAL TECHNOLOGIES</div>	<div>Case Record</div> <div>Doctor Name : Dr.Mayank Doshi, Mumbai</div>		Case Date	06 Aug 2023
			Case Ref	Aug 23/SG
	Case No	CR-3DR-DB -03	Rev No &Date	02/10.2023

3D Printing - Full Denture case in 24 hours

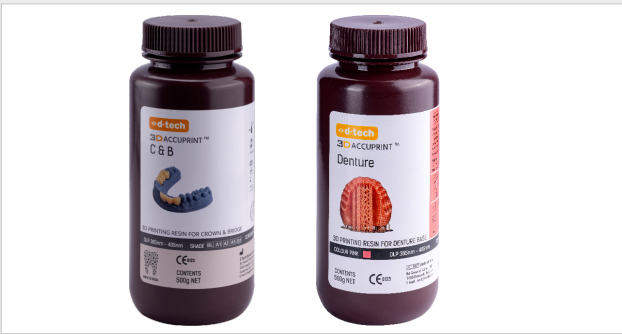

Tooth preparation photos



Post Treatment photos

Product used : Denture &C&B resin



Before planning the implant placement , the patient's final denture was 3D printed using D Tech Accuprint Denture resin for the denture Base and C&B resin for the denture teeth. After post processing both were bonded together using the same C&B resin. Since implants were pre planned digitally, the surgical guide resin was printed using D Tech Accuprint surgical guide resin and during the day of surgery post guided implant placement of the final denture was delivered. With almost 11 months of follow up as on 9th Jul 2024 the patient is now happy with the fit and function of this denture

About the Doctor

Dr. Mayank Doshi is a dentist , Cosmetic and aesthetic dentist and Dental Surgeon in Kandivili west , Mumbai and has an experience of 14 years in these fields.

